

# Abnormal Esophageal Motility in Children With Congenital Central Hypoventilation Syndrome

CHRISTOPHE FAURE, FABIENNE VIARME, GUILLAUME CARGILL, JEAN NAVARRO, CLAUDE GAULTIER, and HA TRANG

Services de Gastroenterologie et de Physiologie, Hôpital Robert Debré, Université Paris VII, Paris, France

**Background & Aims:** Congenital central hypoventilation syndrome, an unexplained disorder of the central control of breathing that may reflect widespread dysfunction of brainstem structures, is regarded as a form of neurocristopathy. Because swallowing-induced peristalsis is centrally controlled and depends on neural crest-derived esophageal innervation, we looked for esophageal dysmotility in patients with congenital central hypoventilation syndrome. **Methods:** Seven patients without dysphagia or any other upper gastrointestinal tract symptoms were studied prospectively (5 girls and 2 boys; median age, 14 years; range, 11–18 years). They were compared with 7 age- and sex-matched controls. Esophageal manometry was performed using a low-compliance infusion system and the station pull-through technique. At least 10 wet swallows were analyzed in each subject. **Results:** Pressure wave propagation was abnormal in all 7 patients (median percentage of swallows propagated, 18%, and range, 0–66; controls, 90% and 80–100;  $P < 0.001$ ). Lower esophageal sphincter relaxation was abnormal in 5 patients (patients, 73% and 53–100; controls, 95% and 90–100;  $P = 0.01$ ). In 2 patients, lower esophageal sphincter pressure was above the 95th percentile of control values. **Conclusions:** These abnormalities are strong evidence of lower esophageal dysfunction in congenital central hypoventilation syndrome. We speculate that the underlying mechanism may be dysfunction of the central structures that control swallowing.

Congenital central hypoventilation syndrome (CCHS) is a rare disorder of central autonomic control of breathing that causes life-threatening hypoxic episodes starting in the neonatal period.<sup>1</sup> Only about 200 cases have been reported in the literature. The etiology and pathophysiology of CCHS remain unknown. However, the clinical manifestations of CCHS may be related to extensive dysfunction of central autonomic control, including cardiovascular control.<sup>2,3</sup> Furthermore, about 20% of CCHS patients have Hirschsprung's disease (HSCR, aganglionic megacolon), a neurocristopathy characterized by absence of intrinsic innervation in a

variable length of the colon.<sup>4,5</sup> Mutations in genes involved in the Rearranged during Transfection (RET)/glial-cell derived neurotrophic factor (GDNF) and endothelin pathways<sup>6,7</sup> are present in some HSCR patients and have been identified also in a few CCHS patients.<sup>8–10</sup> These findings suggest that CCHS may be related to abnormal neural crest development and that a relationship may exist between central control of breathing and the neural crest-derived intrinsic innervation, the enteric nervous system (ENS).<sup>11</sup>

Swallowing is a complex sensorimotor process with coordinated contraction of muscles in pharynx, striated esophagus, and smooth esophagus under the control of a central pattern generator (CPG).<sup>12</sup> Neurons from the nucleus ambiguus project directly to striated muscles and the dorsal motor nucleus of the vagus contains neurons efferent to the smooth muscle region of esophagus projecting on ENS. Dendrites from both nuclei project into the reticular formation near the nucleus of solitary tract corresponding to the CPG of swallowing. Because swallowing-induced peristalsis is coordinated by brainstem structures and requires an intact esophageal ENS, we looked for manometric evidence of esophageal dysmotility in CCHS.

## Materials and Methods

### Patients

Seven patients with CCHS (5 girls and 2 boys) with a median age of 14 years (range, 11–18 years) underwent esophageal manometry in a prospective study. A standardized questionnaire did not detect symptoms of gastroesophageal reflux, dysphagia, or other upper gastrointestinal conditions in any patient at the time of the manometric study. No patients received any medication known to modify gut motility at least

*Abbreviations used in this paper:* CCHS, congenital central hypoventilation syndrome; CPG, central pattern generator; ENS, enteric nervous system; GDNF, glial-cell derived neurotrophic factor; HSCR, aganglionic megacolon; LES, lower esophageal sphincter.

© 2002 by the American Gastroenterological Association

0016-5085/02/\$35.00

doi:10.1053/gast.2002.33062

**Table 1.** Manometry Data in CCHS Patients

CCHS patients	Age (yrs)	Sex	Tracheostomy	LES relaxation						
				LES baseline pressure (mm Hg)	LES residual pressure (mm Hg)	Relaxation of LES baseline pressure (%)	Pressure wave amplitude (mm Hg) <sup>a</sup>	Pressure wave propagation (%)	Gastroesophageal pressure gradient (mm Hg)	
1	11	F	Yes	21.3	9.2	57	60 (40–80)	20	–5.9	
2	11	M	Yes	30.3	4.8	84	35 (10–90)	0	–3.7	
3	12	F	No	8.8	3.1	65	50 (15–110)	0	0	
4	14	F	Yes	25.7	6.7	73	55 (25–85)	45	–4.4	
5	16	F	Yes	23.5	11	53	35 (15–240)	18	–2.2	
6	16	M	No	12.9	0	100	45 (10–80)	66	–3.6	
7	18	F	No	30.9	0	100	30 (15–55)	10	–3.6	
Median	14	—	—	23.5	4.8 <sup>b</sup>	73 <sup>b</sup>	45	18 <sup>c</sup>	–3.6 <sup>b</sup>	
Range	11–18	—	—	8.8–30.9	0–11	53–100	30–60	0–66	–5.9–0	
Controls										
Median	14	—	—	17.3	0.9	95	60	90	–5.9	
Range	10–15.5	—	—	11.9–29.9	0–1.2	90–100	30–70	80–100	–11––5.9	

<sup>a</sup>Median (range).<sup>b</sup>*P* = 0.01.<sup>c</sup>*P* < 0.001 (CCHS vs. controls).

1 month before the study. The appropriate ethics committee (Paris-Bichat-Claude Bernard) approved the study. Informed consent was obtained in writing from the parents of all CCHS patients.

In all 7 patients, CCHS was diagnosed during the neonatal period based on the following criteria: (1) persistent central alveolar hypoventilation ( $P_{aCO_2} > 60$  mm Hg) during sleep detected by polysomnography while the patient spontaneously breathed room air; (2) lack of ventilatory responses to inhaled  $CO_2$ ; (3) and absence of primary lung, neuromuscular, or cardiac disease or brainstem abnormalities that could explain the hypoventilation. Poor sucking was noted in 1 patient (patient 4) during the first few months of life.

Respiratory care was administered as recommended by the state-of-the-art guidelines.<sup>2</sup> All patients were tracheostomized at birth at the time of diagnosis and ventilated at night via the tracheostomy. During late childhood, 6 patients (the exception is patient 4) were successfully transferred to nasal noninvasive ventilation (Table 1). Transition was made before the present esophageal manometric study for 3 patients (3, 6, and 7) and after this study for the 3 others (1, 2, and 5). Endoscopy was performed routinely before decannulation and initiation of nasal ventilation. Although the main goal of endoscopy was to evaluate the nasal, laryngeal, and tracheal airways before decannulation, the esophagus was also examined. In none of the 6 patients did endoscopy show the presence of gastroesophageal reflux or esophagitis.

Therefore, at the time of the esophageal manometric study, 4 patients were ventilated during nocturnal sleep via a tracheostomy cannula, and the 3 others via a nasal mask (Table 1). One girl (patient 4) also had bilateral phrenic nerve stimulation during the day because of diurnal alveolar hypoventilation during spontaneous breathing; she had histologically documented total colonic HSCR (no enteric ganglia on surgical

specimens) and a thoracic ganglioneuroma. None of the patients had mutations in genes encoding RET, GDNF, endothelin-3, or endothelin B receptor.

### Controls

Seven children (5 girls and 2 boys) with a median age of 14 years (range, 10–15.5 years), no known systemic disease associated with esophageal dysmotility, and normal esophagoscopy findings served as controls. They underwent esophageal manometry to investigate dysphagia or odynophagia. Their esophageal trace showed no diffuse esophageal spasm or achalasia, and their symptoms resolved during follow-up.

### Manometry

Esophageal manometry was performed using a low-compliance infusion system (Arndorfer, Arndorfer Medical Specialties, Greensdale, WI) connected to pressure transducers (Statham P23ID, Statham Lab Inc, Puerto Rico). The trace was recorded by a polygraph (Gould ES 2000, Gould Instrument System, Valley View, OH). After a 6-hour fast, a catheter with 4 lumens at 5-cm intervals was introduced into the stomach then withdrawn gradually according to the previously described method without sedation.<sup>13</sup> At least 10 wet swallows were analyzed in each subject.

All traces were analyzed visually by observers blinded to the clinical history of the subjects. (1) Lower esophageal sphincter (LES) pressure was measured at the midrespiratory pressure, with intragastric pressure as the zero reference. LES pressure was calculated as the average of the values recorded by the 4 sensors while the catheter was being pulled through the sphincter. (2) LES relaxation in response to swallowing was expressed as the LES residual pressure and as the percentage of relaxation of LES baseline pressure. (3) Percentage of propagation of esophageal pressure waves was measured in the esoph-

ageal body. (4) The median amplitude of at least 10 pressure waves following wet swallows was determined in each subject. (5) The gastroesophageal pressure gradient was calculated by subtracting the intragastric end-expiratory pressure from the intraesophageal end-expiratory pressure.

### Statistics

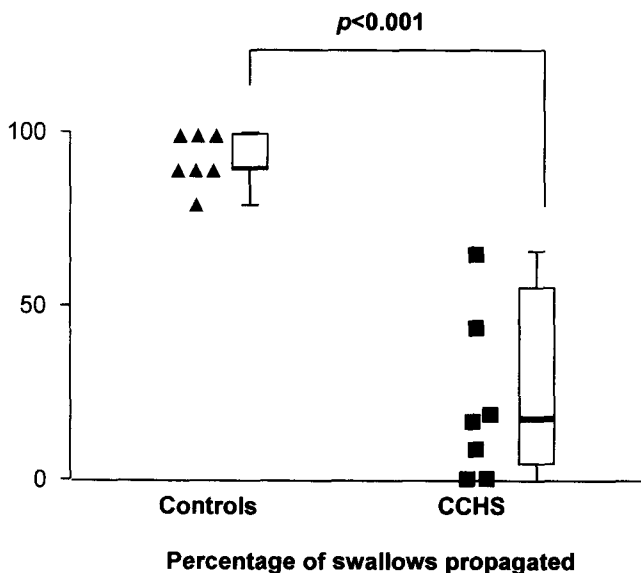
Results for each variable are expressed as the median and range, unless stated otherwise. Comparisons between patients and controls were performed using nonparametric tests (Mann-Whitney test). Spearman's test was used to evaluate correlations among manometric variables and between manometric variables and age in CCHS patients. The  $\chi^2$  test was used to compare LES relaxation between patients and controls and to compare data between tracheostomized and nontracheostomized CCHS patients. A *P* value lower than 0.05 was considered statistically significant.

### Results

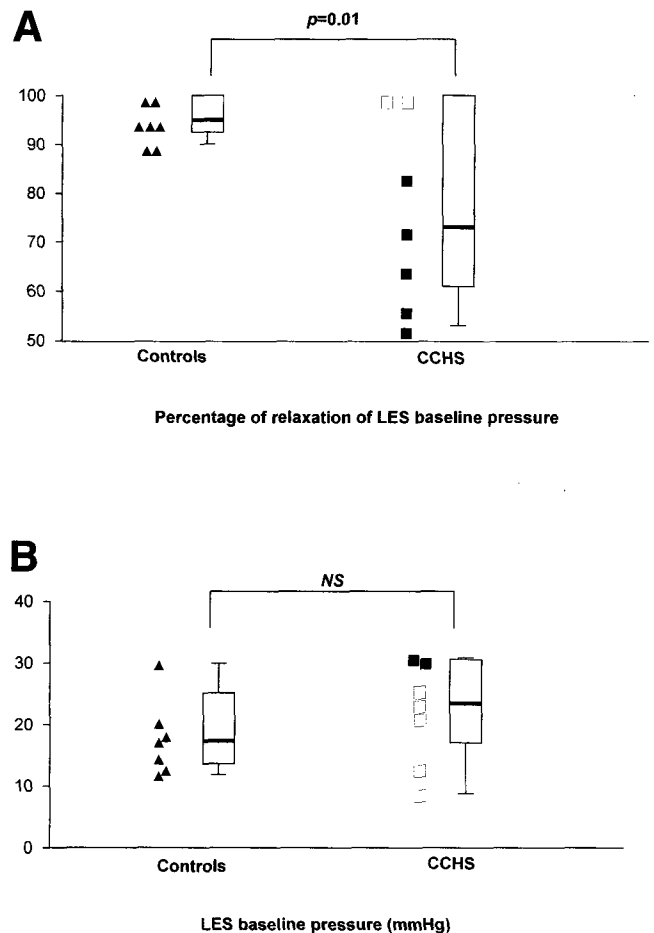
Table 1 shows the esophageal manometry data from the CCHS patients and from the age- and sex-matched controls. Esophageal manometric traces were abnormal in all CCHS patients.

#### Esophageal Body

Pressure wave amplitude was not significantly different between CCHS patients and controls (CCHS, 45 mm Hg, 30–60; controls, 60 mm Hg, 30–70; *P* = 0.2). However, pressure wave propagation was abnormal in all CCHS patients: the median percentage of swallows propagated was significantly lower in the CCHS patients



**Figure 1.** Percentage of swallows propagated in controls and CCHS patients. The **bold horizontal bars** show the median value in each group with the interquartile and 5%–95% ranges. Pressure wave propagation was abnormal in all CCHS patients.



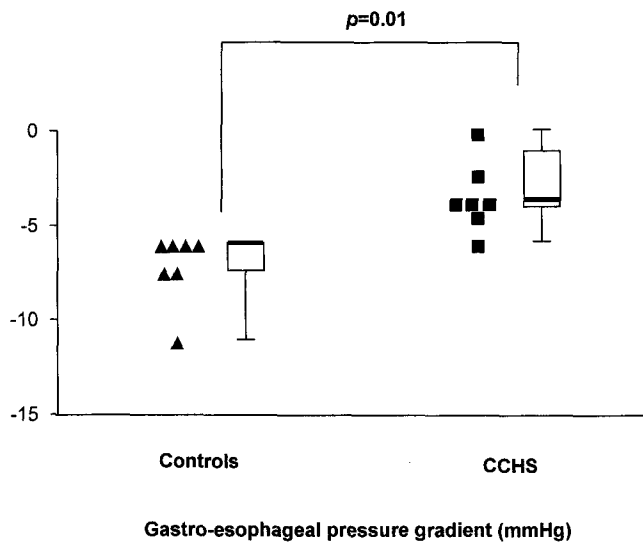
**Figure 2.** (A) Percentage of relaxation of LES baseline pressure in controls and CCHS patients. LES relaxation after wet swallows was abnormal in 5 CCHS patients (■). Median LES relaxation was reduced in CCHS patients. (B) LES pressure was greater than 27.1 mm Hg (95th percentile of values obtained in controls) in 2 CCHS patients (■).

than in the controls (CCHS, 18%, 0–66; controls, 90%, 80–100; *P* < 0.001; Figure 1).

#### LES

LES relaxation after wet swallows was abnormal in 5 CCHS patients (Figure 2). Median LES relaxation was significantly reduced in CCHS patients, as compared with controls (percentage reduction in LES pressure in CCHS, 73%, 53–100; controls, 95%, 90–100; *P* = 0.01 (Figure 2A); LES residual pressure in CCHS, 4.8 mm Hg, 0–11; controls, 0.9 mm Hg, 0–1.2; *P* = 0.01).

Median LES baseline pressure was not significantly different between CCHS patients and controls (CCHS, 23.5 mm Hg, 8.8–30.9; controls, 17.3 mm Hg, 11.9–29.9). However, LES pressure was greater than 27.1 mm Hg (i.e., greater than the 95th percentile of values in controls) in 2 CCHS patients (Figure 2B).



**Figure 3.** The gastroesophageal pressure gradient was higher in the CCHS patients than in the controls.

### Gastroesophageal Pressure Gradient

Median gastroesophageal pressure gradient was higher in the CCHS patients than in the controls (CCHS,  $-3.6$  mm Hg,  $-5.9$  to  $0$ ; controls,  $-5.9$  mm Hg,  $-11$  to  $-5.9$ ;  $P = 0.01$ ) and was not reversed in any of the subjects (Figure 3).

In a girl with HSCR (patient 4), results were within the range of those in the other patients, as shown in Table 1. In the CCHS group, there were no significant correlations among the manometric variables, which were not correlated with age. Data from tracheostomized and nontracheostomized patients were comparable.

### Discussion

The present study using esophageal manometry is the first to show abnormal esophageal motility in a group of adolescent patients with CCHS (median age, 14 years) compared with age- and sex-matched controls. Of the 7 CCHS patients, all had abnormal pressure wave propagation, 5 had abnormal LES relaxation, and 2 had increased LES pressure. These abnormalities strongly suggest lower esophageal dysfunction in CCHS.

Because some CCHS patients have HSCR involving a variable length of the colon, the lower gastrointestinal tract has received considerable attention from investigators studying CCHS.<sup>4,5</sup> In contrast, data on upper gastrointestinal tract symptoms are limited to a few reports during the neonatal period of feeding problems related to poor sucking, swallowing difficulties, and gastroesophageal reflux.<sup>5,14,15</sup> These symptoms resolved within the first few months of life in most patients.

In the present study, we found manometry evidence of lower esophageal dysmotility in a group of adolescent CCHS patients, as compared with controls. Because it was ethically difficult to perform manometry in normal healthy adolescents, we have selected controls as "normal" as possible. However, this may induce some limitation to the study.

Esophageal abnormalities were comparable in patients with and without tracheostomy. Therefore, although delayed laryngeal closure during swallowing has been noted in a few tracheostomized infants,<sup>16</sup> our findings cannot be ascribed to presence of a tracheostomy cannula. The esophageal motility pattern in the CCHS patients showed marked differences from that in controls, with absence of esophageal pressure wave propagation and abnormal LES relaxation. Although our CCHS patients had no upper gastrointestinal symptoms, these manometric findings are strong evidence of specific and reproducible motor abnormalities of the lower esophagus. The clinical significance of esophageal dysmotility in CCHS patients is unknown. The life expectancy in these patients is increasing, and long-term follow-up is crucial.

Our study did not elucidate the etiopathogenic mechanisms underlying the manometric evidence of esophageal dysfunction found in the CCHS patients. However, they suggest a number of hypotheses. Esophageal dysfunction may arise as a consequence of other disorders, of which the most common is probably gastroesophageal reflux. Alternatively, they may reflect a primary motor disorder involving the esophageal smooth muscle itself, the esophageal intrinsic innervation, or the esophageal extrinsic innervation controlled by the central nervous system.<sup>12</sup>

The esophageal manometric pattern found in our CCHS patients was different from those described as consequences of gastroesophageal reflux, in which the esophageal pressure waves are typically multiphased and low in amplitude, and the LES may be hypotonic.<sup>17</sup> Moreover, at the time of the study, all our patients had been free of upper gastrointestinal tract symptoms.

Primary esophageal disorders caused by specific abnormalities in the smooth muscle itself would be expected to produce very low-amplitude esophageal pressure waves with normal propagation, a pattern not found in our CCHS patients.<sup>18</sup> The esophageal dysmotility pattern in our patients was also different from that observed in diseases associated with ENS abnormalities, such as HSCR. Although esophageal dysfunction has been reported in patients with isolated HSCR, LES pressure and relaxation were typically normal.<sup>19,20</sup> The esophageal manometric features in our patients did not meet criteria

for typical complete achalasia but were not incompatible with early-stage achalasia.<sup>21</sup> No pediatric cases of CCHS with achalasia have been reported. Only lifelong follow-up of CCHS patients will tell whether CCHS is associated with an increased risk of achalasia during adulthood.

Another possibility is that esophageal dysmotility in CCHS may be related to a specific dysfunction of the esophageal ENS. This hypothesis rests in part on the fact that RET/GDNF and endothelin pathways are closely related to both the migration and the maturation of the crest-derived cells that form the ENS,<sup>11</sup> as well as to the development of central respiratory structures in animal models.<sup>22–24</sup> That our patients had no mutations in RET/GDNF and endothelin cascade genes does not rule out this hypothesis, because CCHS may involve complex interactive polygenic mechanisms.<sup>2</sup>

However, we suggest that the most likely explanation to the esophageal dysmotility found in CCHS may be a central dysfunction in the modulatory influences from the CPG of swallowing. Widespread dysfunction of brainstem structures is thought to exist in CCHS.<sup>2</sup> Genes from the RET/GDNF and endothelin pathways also seem implicated in the early development of central structures.<sup>22–24</sup> The central control of respiration and cardiovascular function is regulated by structures located in the ventral medullary regions.<sup>25</sup> Also, the CPG of swallowing is located in the nucleus tractus solitarius.<sup>12,26</sup> Recent studies in rats showed evidence of complex interactions between the CPG of swallowing and central structures involved in controlling respiration.<sup>27</sup> Therefore, a reasonable hypothesis is that esophageal dysmotility in CCHS may reflect functional abnormalities in the CPG of swallowing, ascribable either to specific alterations in the CPG itself or to abnormal input from other brainstem regions.

In conclusion, we show manometry evidence of esophageal dysmotility in adolescent CCHS patients. We speculate that these abnormalities may reflect central swallowing dysfunction. The clinical significance of esophageal dysmotility in CCHS patients is unknown, underlining the need for lifelong multidisciplinary follow-up in patients with this disease.

## References

- Mellins RB, Balfour HH, Turino GM, Winters RW. Failure of automatic control of ventilation (Ondine's curse). *Medicine* 1970;49:487–504.
- American Thoracic Society. Idiopathic congenital central hypoventilation syndrome. Diagnosis and management. *Am J Respir Crit Care Med* 1999;160:368–373.
- Woo MS, Woo MA, Gozal D, Jansen MT, Keens TG, Harper RM. Heart rate variability in congenital central hypoventilation syndrome. *Pediatr Res* 1992;31:291–296.
- Haddad GG, Mazza NM, Defendini R, Blanc WA, Driscoll JM, Epstein MAF, Epstein RA, Mellins RB. Congenital failure of automatic control of ventilation, gastrointestinal motility and heart rate. *Medicine* 1978;57:517–526.
- Croaker GDH, Shi E, Simpson E, Cartmill T, Cass DT. Congenital central hypoventilation syndrome and Hirschsprung's disease. *Arch Dis Child* 1998;78:316–322.
- Ederly P, Lyonnet S, Mulligan LM, Pelet A, Dow E, Abel L, Holder S, Nihoul-Fekete C, Ponder BA, Munnich A. Mutations of the RET proto-oncogene in Hirschsprung's disease. *Nature* 1994;367:378–380.
- Attié T, Till M, Pelet A, Amiel J, Ederly P, Boutrand L, Munnich A, Lyonnet S. Mutation of the endothelin-receptor B gene in the Waardenburg-Hirschsprung disease. *Hum Mol Genet* 1995;4:2407–2409.
- Amiel J, Salomon R, Attié T, Pelet A, Trang H, Mokthari M, Gaultier C, Munnich A, Lyonnet S. Mutation of the RET-GDNF signaling pathway in Ondine's curse. *Am J Hum Genet* 1998;62:715–717.
- Bolk S, Angrist M, Xie J, Yanagisawa M, Silvestri M, Weese-Mayer DE, Chakravarti A. Endothelin-3 frameshift mutation in congenital central hypoventilation syndrome. *Nat Genet* 1996;13:395–396.
- Sakai T, Wakizaka A, Matsuda H, Nirasawa Y, Itoh Y. Point mutation in exon 12 of the receptor tyrosine kinase proto-oncogene RET in Ondine-Hirschsprung syndrome. *Pediatrics* 1998;101:924–926.
- Gershon MD. Lessons from genetically engineered animal models. II. Disorders of enteric neuronal development: insights from transgenic mice. *Am J Physiol (Gastrointest Liver Physiol)* 1999;G262–G267.
- Jean A. Brainstem organization of the swallowing network. *Brain Behav Evol* 1984;25:109–116.
- Boige N, Faure C, Cargill G, Mashako MN, Cordeiro-Ferreira G, Viarme F, Cezard JP, Navarro J. Manometrical evaluation in visceral neuropathies in children. *J Pediatr Gastroenterol Nutr* 1994;19:71–77.
- Guilleminault C, McQuitty J, Ariagno RL, Challamel MJ, Korobkin R, McClead RE. Congenital central alveolar hypoventilation in six infants. *Pediatrics* 1982;70:684–694.
- Marcus CL, Jansen MT, Poulsen MK, Keens SE, Nield TA, Lipsker LE, Keens TG. Medical and psychosocial outcome of children with congenital central hypoventilation syndrome. *J Pediatr* 1991;119:888–895.
- Abraham SS, Wolf EL. Swallowing physiology of toddlers with long-term tracheostomies: a preliminary study. *Dysphagia* 2000;15:206–212.
- Singh P, Adamopoulos A, Taylor RH, Colin-Jones DG. Oesophageal motor function before and after healing of oesophagitis. *Gut* 1992;33:1590–1596.
- Tomomasa T, Itoh Z, Koizumi T, Kitamura T, Suzuki N, Matsuyama S, Kuroume T. Manometric study on the intestinal motility in a case of megacystis-microcolon-intestinal hypoperistalsis syndrome. *J Pediatr Gastroenterol Nutr* 1985;5:307–310.
- Faure C, Ategbo S, Feirrer GC, Bellaiche M, Viarme F, Cargill G, Boige N, Aigrain Y, Cezard JP, Navarro J. Duodenal and oesophageal manometry in total colonic aganglionosis. *J Pediatr Gastroenterol Nutr* 1994;18:193–199.
- Staiano A, Corazziari E, Andreotti MR, Clouse RE. Esophageal motility in children with Hirschsprung's disease. *Am J Dis Child* 1991;145:310–313.
- Hirano I, Tatum RP, Guoxiang S, Sang Q, Joehi RJ, Kahrilas PJ. Manometric heterogeneity in patients with idiopathic achalasia. *Gastroenterology* 2001;120:789–798.
- Pachnis V, Mankoo B, Costantini F. Expression of the c-ret proto-oncogene during mouse embryogenesis. *Development* 1993;119:1005–1017.
- Yanagisawa H, Yanagisawa M, Kapur RP, Richardson JA, Williams SC, Clouthier DE, de Wit D, Emoto N, Hammer RE. Dual

- genetic pathways of endothelin-mediated intercellular signaling revealed by targeted disruption of endothelin converting enzyme-1 gene. *Development* 1998;125:825-836.
24. Burton MD, Kawashima A, Brayer JA, Kazemi H, Shannon DC, Schuchardt A, Costantini F, Pachnis V, Kinane TB. RET proto-oncogene is important for the development of respiratory CO<sub>2</sub> sensitivity. *J Auton Nerv Syst* 1997;63:137-143.
  25. Nattie E. CO<sub>2</sub>, brainstem chemoreceptors and breathing. *Progr Neurobiol* 1999;59:299-331.
  26. Aziz Q, Thompson DG. Brain-gut axis in health and disease. *Gastroenterology* 1998;114:559-578.
  27. Broussard DL, Lynn RB, Wiedner EB, Altschuler SM. Solitary premotor neuron projections to the rat esophagus and pharynx: implications for control of swallowing. *Gastroenterology* 1998;114:1268-1275.
- 
- Received July 25, 2001. Accepted January 17, 2002.  
Address requests for reprints to: Christophe Faure, M.D., Division of GI & Nutrition, Ste Justine Hospital, University of Montreal, 3175 Cote Ste Catherine Road, Montreal, QC Canada H3T 1C5. e-mail: christophe.faure.hsj@sss.gouv.qc.ca; fax: (514) 345-4999.  
Supported by a grant from Contrat de recherche clinique CIC-INSERM-Hôpitaux 1997.